



**PATIENT**

Rocko Biszmaier

**SPECIES**

Feline

**BREED**

DSH

**SEX**

Male Neutered

**AGE**

5 years

**WEIGHT**

7.66lbs

**INTERPRETED BY**

Maggie Machen Lamy,  
DVM, DACVIM  
(Cardiology)

**IMAGING PERFORMED BY**

A. Nicastro, DVM

**HOSPITAL NAME**

Flowertown Animal  
Hospital

**REFERRING VET**

Dr. Randinelli

**INVOICE**

29094

**DATE**

2/17/23

**PRESENTING CLINICAL SIGNS**

History: Grade 2-3/6 heart murmur. History of azotemia since 2017. Abnormal kidneys on ultrasound in 2017. Azotemia now worse. Decreased appetite; occasional vomiting. BP: 150-162mmHg. Tachycardia.

-Abnormal PE/Chem/CBC/UA Results: Creat. 5.1, BUN - 111; electrolytes not assessed; Usg - 1.048; 1+ proteinuria, inactive sediment.

**ECHOCARDIOGRAM FINDINGS**

2D, m-mode, color flow and doppler imaging is available. The left ventricular wall is mildly remodeled with focal septal thickening. The remainder of the LV wall measures normal. There is a mildly hyperechoic endocardium consistent with fibrosis. The papillary muscles are mildly remodeled and hyperechoic. The left atrium is normal in size. The right atrium is normal in size. The right ventricle appears normal. The mitral valve is normal in structure and mobility. No MR. Trace TR. Blood flow through the RVOT and LVOT is normal in velocity. No pleural or pericardial effusion seen. No obvious cardiac tumors.

**CARDIAC CHART**

| FELINE CARDIAC PARAMETERS  | BODY WEIGHT (kg) | HR (BPM)                        | IVSd (cm) (Moise, Pipers)                | LVIDd (cm) (Moise, Pipers) | LVWd (cm) (Moise, Pipers) | FS (%)         | EF (%)      |
|--|------------------|---------------------------------|--|----------------------------|---------------------------|----------------|-------------|
| NORMAL PARAMETER   | -----            | 150-240                         | 0.35-0.55                                | <2 (mean 1.5)              | 3.5-0.55                  | 35-67          | 80-100      |
| PATIENT  | 3.5              | NM                              | 0.62                                     | 1.27                       | 0.51                      | 58             | 90          |
| FELINE CARDIAC PARAMETERS  | LA/AO (Boon)     | LA/AO HEART BASE (Swe) (Abbott) | LA 2D short axis Base view (cm) (Abbott) |                            | LVOT VEL (m/s)            | RVOT VEL (m/s) | E max (m/s) |
| NORMAL   | <1.5             | <1.3                            | <1.2                                     |                            | <1.6                      | <1.3           | <0.9        |
| PATIENT  | NM               | 1.1                             | 1.1                                      |                            | 1.5                       | 0.9            | NM          |
| <p><i>*Note: All measurements based upon multi-modal images and methods. An average value is reported.</i><br/>                     Adapted from June Boon, Veterinary Echocardiography, 1998<br/>                     Abbott J &amp; MacLean H JVIM 2006;20: 111-119, Moise et al. Am J Vet Res 47:1476, 1986. Pipers et al. Am J Vet Res 40:882, 1979.</p> |                  |                                 |  |                            |                           |                |             |

**INTERPRETATION OF THE FINDINGS & FURTHER RECOMMENDATIONS**

Mild focal LV hypertrophy is present in addition to mild LV remodeling, which may be indicative of early hypertrophic disease or may simply represent a normal variant. Regardless, the LA remains normal which would indicate clinical stability. Serial echocardiography will be necessary to determine progression and clinical significance. Additionally, no definitive cause is identified for the murmur in this study, making it likely benign and secondary to tachycardia/stress. Monitor BP/T4 every 6-12 months.

With a normal LA dimension, no medications are indicated. Prognosis is open pending assessing for progression.

Given these findings, anesthetic risk is mild, however any cat with this degree of fibrosis and diastolic dysfunction will be at risk for iatrogenic IV fluid overload should they be needed in the future.



**PATIENT**

Rocko Biszmaier

Monitor for any development of clinical signs, including labored breathing or signs of a blood clot (paralysis, neurologic change).

**SPECIES**

Feline

A recheck echocardiogram is recommended in 6-12 months to screen for any evidence of progression.

**BREED**

DSH

**SEX**

Male Neutered

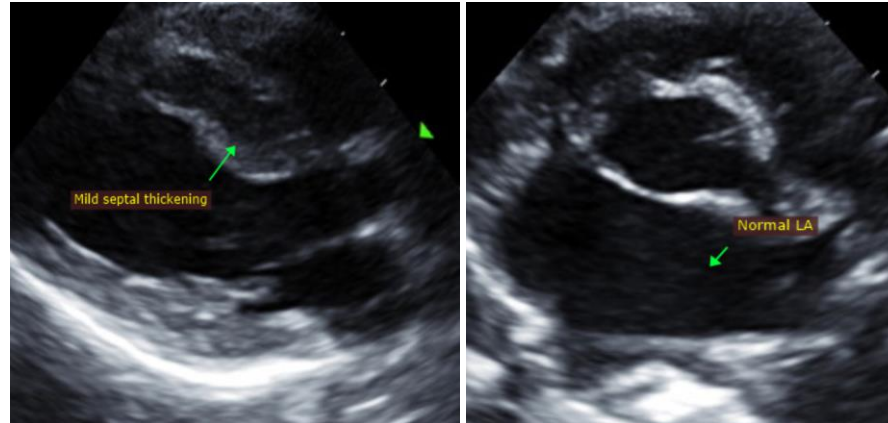
**AGE**

5 years

**WEIGHT**

7.66lbs

**IMAGES**



The information and recommendations provided are based on the images presented by the referring veterinarian. No evaluation can be communicated regarding pathology that was not visible in the image/video clips provided.

**INTERPRETED BY**

Maggie Machen Lamy,  
DVM, DACVIM  
(Cardiology)

Thank you for this referral. This report was generated using transcription software, and minor dictation errors may be present. If the clinical or image interpretation does not parallel your findings or if I can be of any further assistance, please contact me.

**IMAGING PERFORMED BY**

A. Nicastro, DVM

**Maggie Machen Lamy, DVM**  
Diplomate of the American College of Veterinary Internal Medicine (Cardiology)  
info@sonopath.com

**HOSPITAL NAME**

Flowertown Animal  
Hospital

**REFERRING VET**

Dr. Randinelli

**INVOICE**

29094

**DATE**

2/17/23